

Castration as a Treatment for Seminoma Intratubular Case in Horse

Budhy Jasa Widyananta^{1*}, Fitri Dewi Fathiyah², Wiwid Rhuwaida³

¹Faculty of Veterinary Medicine, Bogor Agricultural University; ²Equestina Equine Health Services;

³Equestrina Equine Health Services

*email: dr.budhy_nanta@yahoo.com

Keywords: castraton, horse, seminoma, testicle enlargement.

INTRODUCTION

Quality Stallions are one of the most expensive aset in the horse farm. Testicular swelling quite common found without specific diagnosis due to lack of experience. Varied supportive diagnosis is needed to confirm the cause. A thirteen years old horse crossbreed stallion had a history of progressive testicular enlargement.

CASE REPORT

Brown, crossbreed horse named Bumble Bee has been stop from riding school activity to prevent further enlargement on his right testicle (figure 1). Physical examination did not show any significant findings. Heart rate was 32 bpm, respiration rate 40 bpm, and temperature 37.9°C. Other dehydration value such as skin recoil was 1 second, Cafillary Refill Time (CRT) 1 second and mucous membrane color was pink and moist. Behaviour, appetite, urination and defecation were normal.

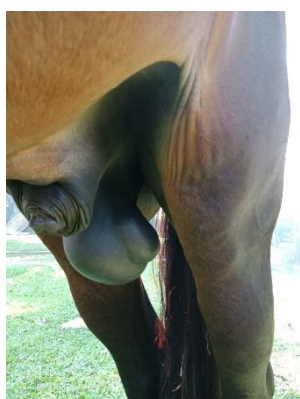


Figure 1 Enlargement Right Testis

Further examination were performed to differentiate from scrotal hernia by appling stetoscope and ultrasound probe around the testicle and spermatic cord. No hernia ring and organs were found.

Diagnosis was made as neoplasia like tumor. Prognosis varied to dubious to guarded if the neoplasia spread to the testicular invasive vesel. Differential diagnosis were orchitis (infection or

trauma), teratomas (occur in young animal), interstitial cell tumors and sertoli cell tumour. Differential diagnosis were Orchitis (infection or trauma), interstitial cell tumour, sertoli cell tumour, and testicular torsion.

Recommended treatment were castration procedure for one or both testicles and sample biopsy. Both testicle were taken out by open technique castration under general anesthesia with ketamin xilazine combination drugs. Antibiotic and anti inflammatory were given for a week. Incision site were recovered within a week without any complication.

Surgical specimens and tissues were taken after castration procedure and fixed in 10% neutral buffered formalin to be send to the laboratory .

RESULT AND DISCUSSION

Diagnosis for neoplasia was difficult to be made by physical exam only therefore supported by ultrasound procedure. Knottenbelt, *et al* (2003) suggest following ultrasonographic examination (figure 2) a presumptive diagnosis of unilateral seminoma was made. As accurate determination of the incidence of equine testicular tumours is difficult as many horses are castrated at a young age (Valentine and Weinstock, 1986).

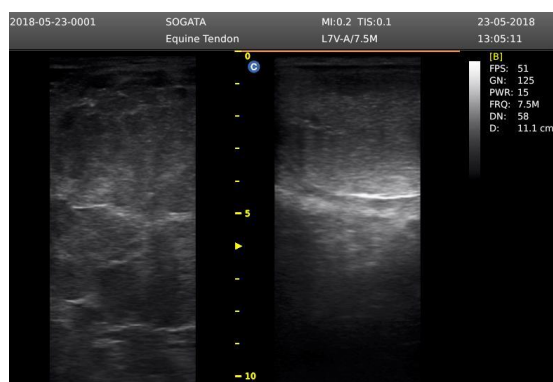

Figure 2 Ultrasonograph Result Right Testicle and Left Testicle

According to Valentine and Weinstock (1986) and Peterson (1984), testicular neoplasia is rare in horse. No seminomas were found among 1404 necropsio and 846 biopsy spesimen in

another survey of equine neoplasia (Trigo *et al* 1984).

Testicles were collected post castration showed an enlargement of the right incised testicle. The right testicle was measured for 10 cm diameter and the left testicle was measure for 7cm diameter (figure 3). Testicle contained multiple soft bulging nodules, and well encapsulated and diagnosed as seminoma.

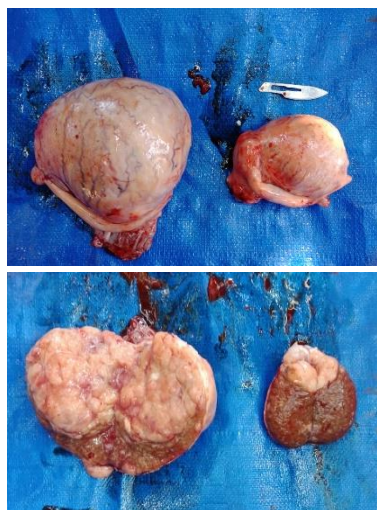


Figure 3 Testicle Post Surgery

Seminoma and Teratomas is the most common tumour of the equine testicle (Knottenbelt, *et al*, 2003 and Peterson, 1984). Seminoma derived from basal spermatogonia cell within the seminiferous epithelium. They do not have any endocrinological function or implication (Knottenbelt, *et al*, 2003).

An association between cryptorchidism and seminomas has been reported in man dogs and horses (Trigo *et al*, 1984) eventhough that was not the issue for Bumble Bee case. It has two testicles with right testicle enlargement. Knottenbelt, *et al*, (2003) also reported that Seminoma can affect cryptorchid or descended testis.

After castration procedure, the horse was still under vet supervision. Any lump or growing on his body should be reported as soon as possible. Knottenbelt, *et al* (2003) reported that Seminoma in horses probably more aggressive than in other species, with well recognised tendency to malignancy and metastasis, in particular to thorax and abdominal organs within 2 years of removal of the affected testicle. Metastasis spread is clearly an early process. Trigo *et al* (1984) added, all equine seminoma tumours should be regarded as potentially malignant and the prognosis should reflect that. Seminoma is benign tumour of the testicle but it might metastase to the regional lymphonode or internal organ. A survey among 13 veterinary schools revealed the presence of only six seminomas. One of them metastatic in horses.

CONCLUSION

The testicular swelling was caused by seminoma tumour.

Diagnostic confirmation Knottenbelt, *et al* (2003):

1. Ultrasonographic findings are distinctive and enable a diagnosis to be made with reasonable certainty. The affected testicle may reveal a diffuse by heterogenous parenchyma. The testicle is usully diffusely hypoechoic, with ill defined regions of hyperechoigenicity giving the appearance of hypoechoic nodules throughout the testicular parenchyma. Normal testicular tissue may or may not be seen, since the tumour gradually alterates the normal structures. An echogenic band, represnting a pseudo capsules may be seen surrounding the testicle.
2. Biopsy by hollow needle methods is definitive but since most affected test are noticable enlarged. Removal is the best diagnostic approach.

Management Knottenbelt, *et al* (2003):

1. The affected testicle should be removed as soon as possible and submitted for historical examination.
2. In theory, intravenous 5 fluorouracil should be helpffull but it is extremelly poorly tolerated in horses.

ACKNOWLEDGMENTS

The author would like to thanks to Anantya Riding Club and Equestrina Equine Health Service Management for their support to the whole process.

REFERENCES

- [1] BA Valentine and D Weinstock. Metastatic Testicular Embryonal Carcinoma in Horse. *Vet. Pathol.* 23:92-96 (1986).
- [2] Dean E. Peterson. Equine Testicular Tumours *Journal of Equine Veterinary Science.* <https://doi.org/10.1016/30737-0806> (89) 80101-X.
- [3] Derek C. Knottenbelt, Katie Snalune, Janet Patterson Kane. 2003. *Clinical Equine Oncholgi E-Book.* WB Saunders. Edinburgh
- [4] Trigo FJ, Miller RA, Torbec RL. 1984. Metastatic Equin Seminoma: Report of two cases. *Vet. Pathol.* 21: 259 – 260.